

## CASE REPORT

# Management of Periapical Cyst in a Tooth with Immature Apex using Biodentine

<sup>1</sup>Deepika C Mod, <sup>2</sup>Kamlesh Bhorania, <sup>3</sup>Pranav Kharod

## ABSTRACT

A 12-year-old male patient presented with history of trauma 2 years back. The tooth had incomplete root formation and a periapical radiolucency. Attempts were made to complete the apexification procedure. Instead of using common material mineral trioxide aggregate (MTA) for apexification, it was decided to operate this case with Biodentine. Complete orthograde obturation was done with Biodentine, followed by root resection and removal of excess material. At 3 months follow-up there was significant healing and bone formation in the periapical region, so Biodentine can be used as an orthograde obturation material and can replace dentin in large spaces in cases with blunder-buss apex, and can provide an effective seal.

**Keywords:** Biodentine, Blunder-buss apex, Mineral trioxide aggregate.

**How to cite this article:** Mod DC, Bhorania K, Kharod P. Management of Periapical Cyst in a Tooth with Immature Apex using Biodentine. *Int J Prev Clin Dent Res* 2016;3(3):225-227.

**Source of support:** Nil

**Conflict of interest:** None

## INTRODUCTION

Injury to anterior teeth is a common event. Injury to a tooth with immature apex requires a treatment approach that assures a tight seal at apex, which ensures complete biologic and functional restoration of the tooth involved. Orthograde obturation of root canal with blunder-buss apex always poses a challenge.<sup>1</sup> Mineral trioxide aggregate (MTA) is commonly used to create the barrier at the apex in such cases. One of the major problems posed by MTA is handling properties and long time to set.<sup>2</sup> Another material with largely improved handling properties, Biodentine (Septodont), was introduced in 2011. It is a calcium silicate-based material, having biocompatibility

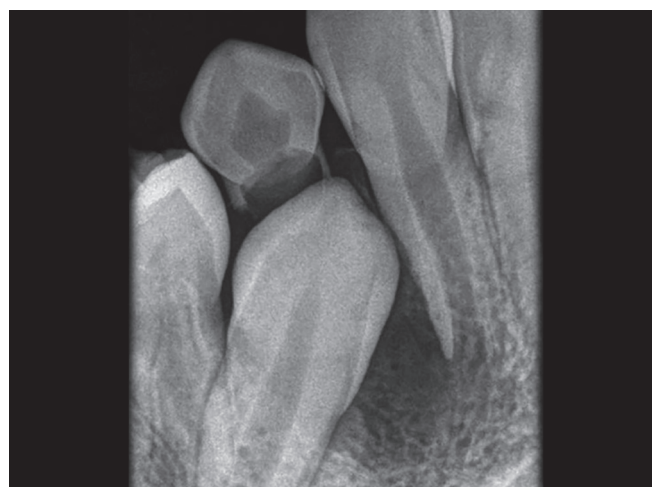similar to MTA.<sup>3,4</sup> This case report is management of tooth with immature apex with periapical lesion where Biodentine is used as complete root canal filling material. Follow-up after 3 months showed significant healing.

## CASE REPORT

A healthy 12-year-old male patient reported to Department of Conservative Dentistry at College of Dental Sciences, Amargadh with chief complaint of pain and swelling in relation with maxillary right lateral incisor. The patient revealed history of trauma around 2 years back. Clinical examination revealed a soft fluctuating tender swelling in the buccal vestibule. Radiograph revealed periapical radiolucency with immature root apex of lateral incisor (Fig. 1). Tooth gave negative response to vitality testing.

Access cavity was prepared in lateral incisor followed by cleaning and preparation of canal with 0.5% NaOCl (sodium hypochlorite) and saline. After cleaning and shaping, calcium hydroxide was placed as intra-canal medicaments and renewed after 3 weeks, which was followed up for 3 months. After 3 months there was no sign of apical barrier formation, and improved healing was noted in periapical radiolucency (Fig. 2).

Thus, we decided to go for orthograde filling of root canal with Biodentine followed by enucleation of periapical lesion and smoothening of root apex. Canal was obturated with Biodentine as root canal filling material to achieve a dense seal at apex (Fig. 3).



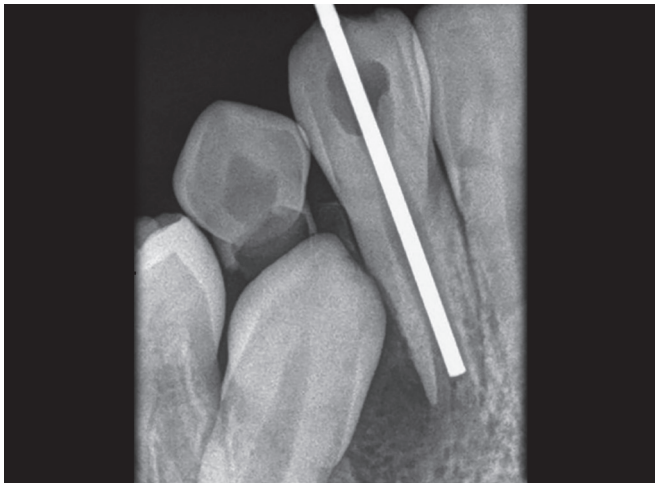
**Fig. 1:** Preoperative image showing periapical radiolucency in relation to the lateral incisor with open apex

<sup>1</sup>Professor, <sup>2</sup>Reader, <sup>3</sup>Senior Lecturer

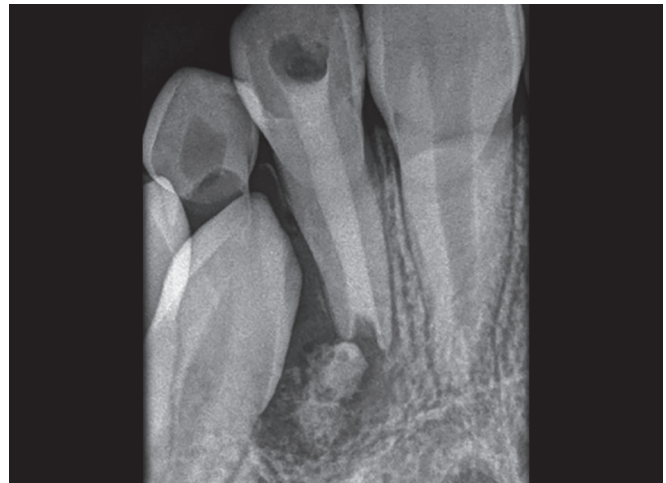<sup>1,3</sup>Department of Conservative Dentistry and Endodontics  
College of Dental Sciences, Bhavnagar, Gujarat, India

<sup>2</sup>Department of Conservative Dentistry and Endodontics  
Mansarovar Dental College Hospital and Research Centre  
Bhopal, Madhya Pradesh, India

**Corresponding Author:** Pranav Kharod, Senior Lecturer  
Department of Conservative Dentistry and Endodontics, College  
of Dental Sciences, Amargadh, Bhavnagar, Gujarat, India  
Phone: +919033247097, e-mail: vikas873@yahoo.com



**Fig. 2:** Cleaned and shaped canal; plugger was checked to be reaching in the apical third of the root



**Fig. 3:** Root canal completed with Biodentine

After raising a double vertical trapezoidal flap, periapical pathosis and extra Biodentine was removed from periapical area, which was followed by smoothing at root apex and finally sutures were placed. Patient was recalled after 1 week for suture removal and regular follow-up was taken for 3 months, which showed improved healing in radiograph (Figs 4 and 5).

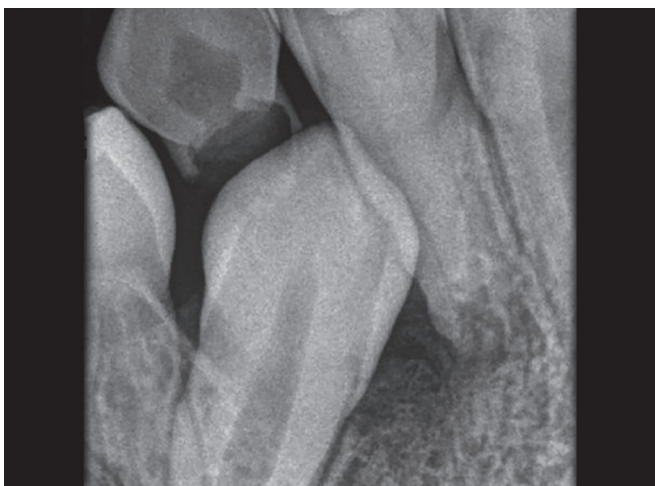## DISCUSSION

Management of cases with open apex poses a problem during management of traumatic injuries involving permanent teeth. Especially, in cases where apex have not been closed up to a level, then conventional root canal can be undertaken. Apical seal with conventional gutta-percha is best when the apical terminus is smallest possible.<sup>5</sup> So when the apical terminus is larger due to incomplete root formation, it is advisable either to engage regenerative procedures to reduce the size of it or obtain apical seal with alternative methods.<sup>6</sup>

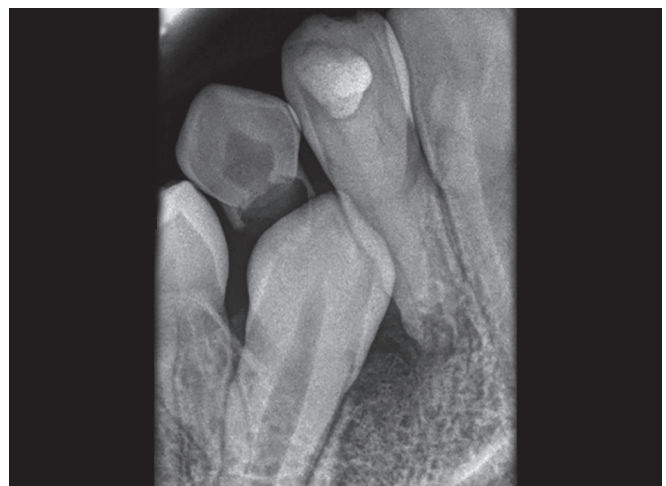Regeneration protocol is the procedure to restart the root formation once it has stopped due to any injury. It was not carried out mainly due to decreased success rate in teeth with periapical radiolucency, and more time had lapsed between the traumatic injury and the treatment.<sup>7</sup>

Mineral trioxide aggregate is one of the newer materials introduced in endodontics and has shown very good tissue response when used in apexification procedures. However, few of the drawbacks with this material are low compressive strength, long setting time, and difficult handling properties.<sup>8</sup>

Biodentine is developed as a permanent dentinal substitute to be used where original dentin is lost. It is available as powder in a capsule and liquid in a pipette. Powder consists of tricalcium silicate and dicalcium silicate which are the principal components of MTA. Liquid for mixing with powder consists of calcium chloride and water-soluble polymer. Marginal sealing ability of calcium silicate-based materials is attributed to its



**Fig. 4:** Postoperative radiograph after apicoectomy was performed and root resection was carried out. Reduction of the apical radiolucency is evident



**Fig. 5:** Postoperative radiograph after follow-up of 3 months showing improved healing in the periapical region

ability to produce surface apatite crystals when it comes in contact with phosphates available in tissue fluids.<sup>1,9</sup>

Placement of Biodentine as apical plug is technique sensitive. As sealing material extruded periapically, it may set before it disintegrates or gets resorbed. This might result in the persistence of inflammatory process.<sup>10,11</sup> In this case, as there was chronic periapical pathology, it was decided to fill the root canal completely with Biodentine to ensure dense filling at the apex, followed by surgical enucleation of the lesion. As Biodentine shows great improvement in properties compared to other calcium silicate materials, as well as it has short setting time, it was selected for this case.<sup>6,8</sup>

## CONCLUSION

The use of Biodentine as complete root canal filling material in cases of immature apex explores a new treatment option. The excellent biocompatibility and shorter setting time makes it a promising material for single-visit treatment of such cases. However, long-term clinical trials and follow-ups are required.

## REFERENCES

1. Barthel CR, Moshonov J, Shuping G, Orstavik D. Bacterial leakage vs. dye leakage in obturated root canals. *Int Endod J* 1999 Sep;32(5):370-375.
2. Camilleri J, Pitt Ford TR. Mineral trioxide aggregate: a review of the constituents and biological properties of the material. *Int Endod J* 2006 Oct;39(10):747-754.
3. About I, Laurent P, Tecles O. Bioactivity of Biodentine™ a Ca<sub>3</sub>SiO<sub>5</sub>-based dentine substitute. Oral session. IADR Congress July 2010, Barcelona, Spain.
4. Franquin, JC, Marie O. Physical properties of a new Ca<sub>3</sub>SiO<sub>5</sub>-based dentin substitute poster sessions, IADR Congress July 2010, Barcelona, Spain.
5. El Debb ME, Xuckett KJ, Messer H. Apical leakage in relation to radiographic density of guttapercha using different obturation techniques. *J Endod* 1985 Jan;11(1):25-29.
6. Xavier CB, Weismann R, Oliveira MG, Demarco FF, Pozza DH. Root-end filling materials: apical micro leakage and marginal adaptation. *J Endod* 2005 Jul;31(7):539-542.
7. Yang J, Yuan G, Chen Z. 2016 Pulp regeneration: Current approaches and future challenges. *Front Physiol* 2016 Mar; 7:58.
8. Torabinejad M, Hong CU, Mc Donald F, Pitt Ford TR. Physical and chemical properties of a new root end filling material. *J Endod* 1995 Jul;21(7):349-353.
9. Camps J, Pashley D. Reliability of dye penetration studies. *J Endod* 2003 Sep;29(9):592-594.
10. About I, Raskin A. Cytotoxicity and genotoxicity of a new material for direct posterior fillings. *Eur Cells Mater* 2005;10(4):23.
11. Tobón-Arroyave SI, Restrepo-Pérez MM, Arismendi-Echavarría JA, Velásquez-Restrepo Z, Marín-Botero ML, García-Dorado EC. Ex vivo microscopic assessment of factors affecting the quality of apical seal created by root-end fillings. *Int Endod J* 2007 Aug;40(8):590-602.